

**US
INVESTIGATIONS
OF
BRACHIAL VEINS**



TERMINOLOGY

Basilic vein
Medial brachial vein
Lateral brachial vein

COMMON BRACHIAL VEIN

PROXIMAL / CRANIAL
DISTAL / CAUDAL

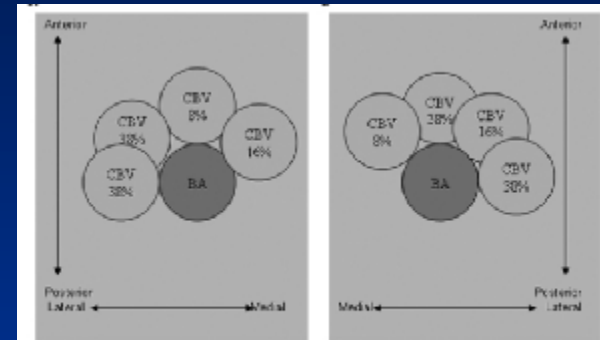


Figure 6 Graphic representation of syntopy of the common brachial vein, in a cross sectional view, at the intermediate point of the proximal third of the right (A) and left arm (D)

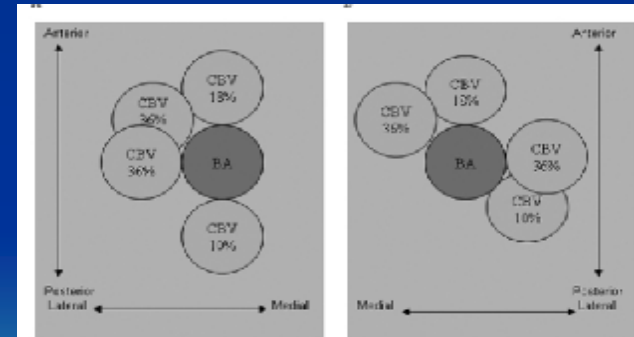


Figure 5 Graphic representation of syntopy of the common brachial vein, in a cross-sectional view, at the intermediate point of the medial third of the right (A) and left arm (B)


US BRACHIAL VEINS INVESTIGATION SUITABLE VEINS

- **TRANSVERSE SECTION SCANNING OF THE Arm
ANTECUBITAL FOSSA TO THE SHOULDER**
- **GUIDED BY BRACHIAL ARTERY**
- **Median nerve**
- **LONGITUDINAL SECTION: valve and completion**

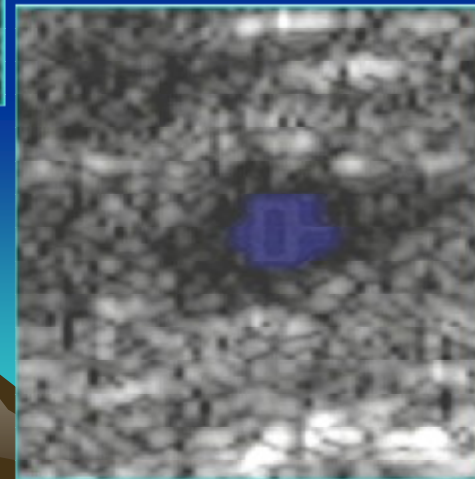
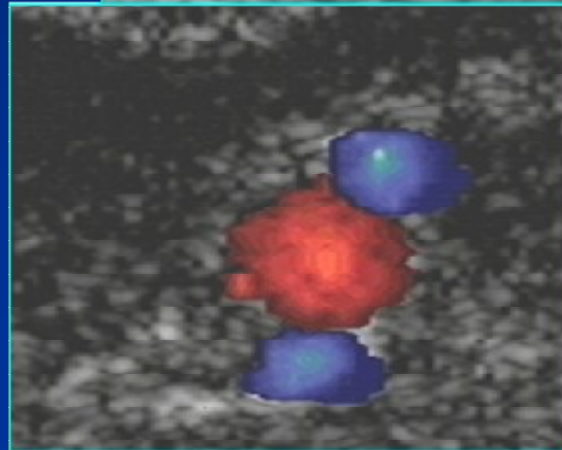
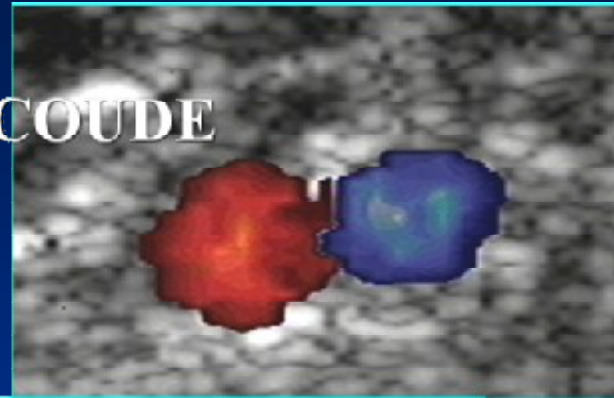


SINGLE TRUNC BRACHIAL/BASILIC VEIN

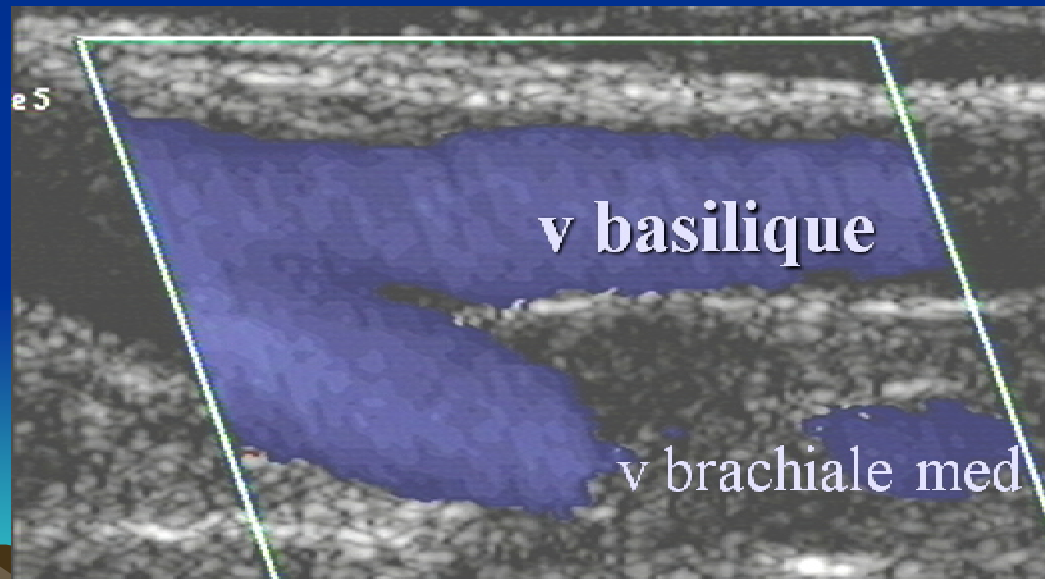
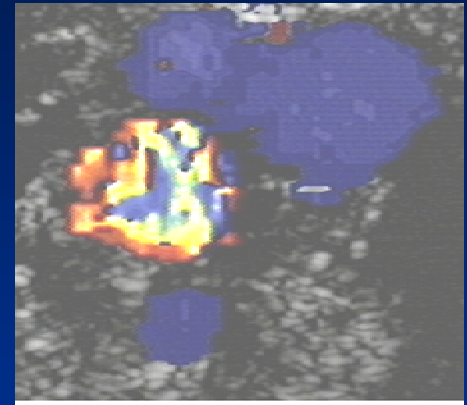
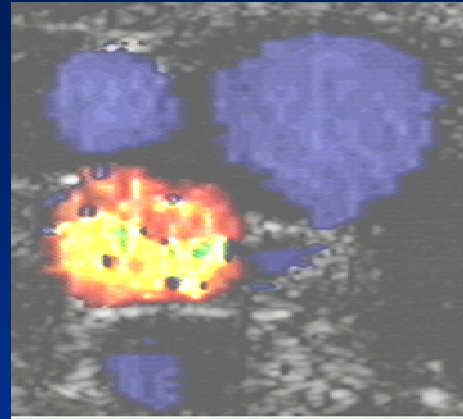
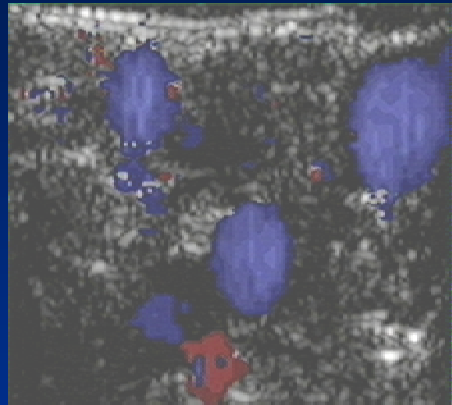
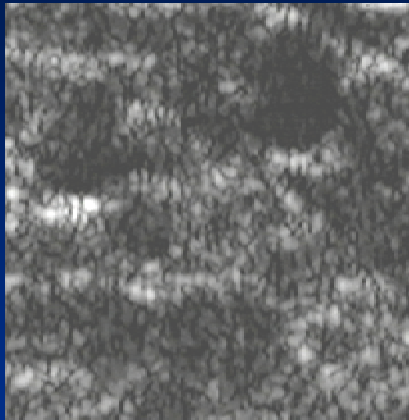
CBV



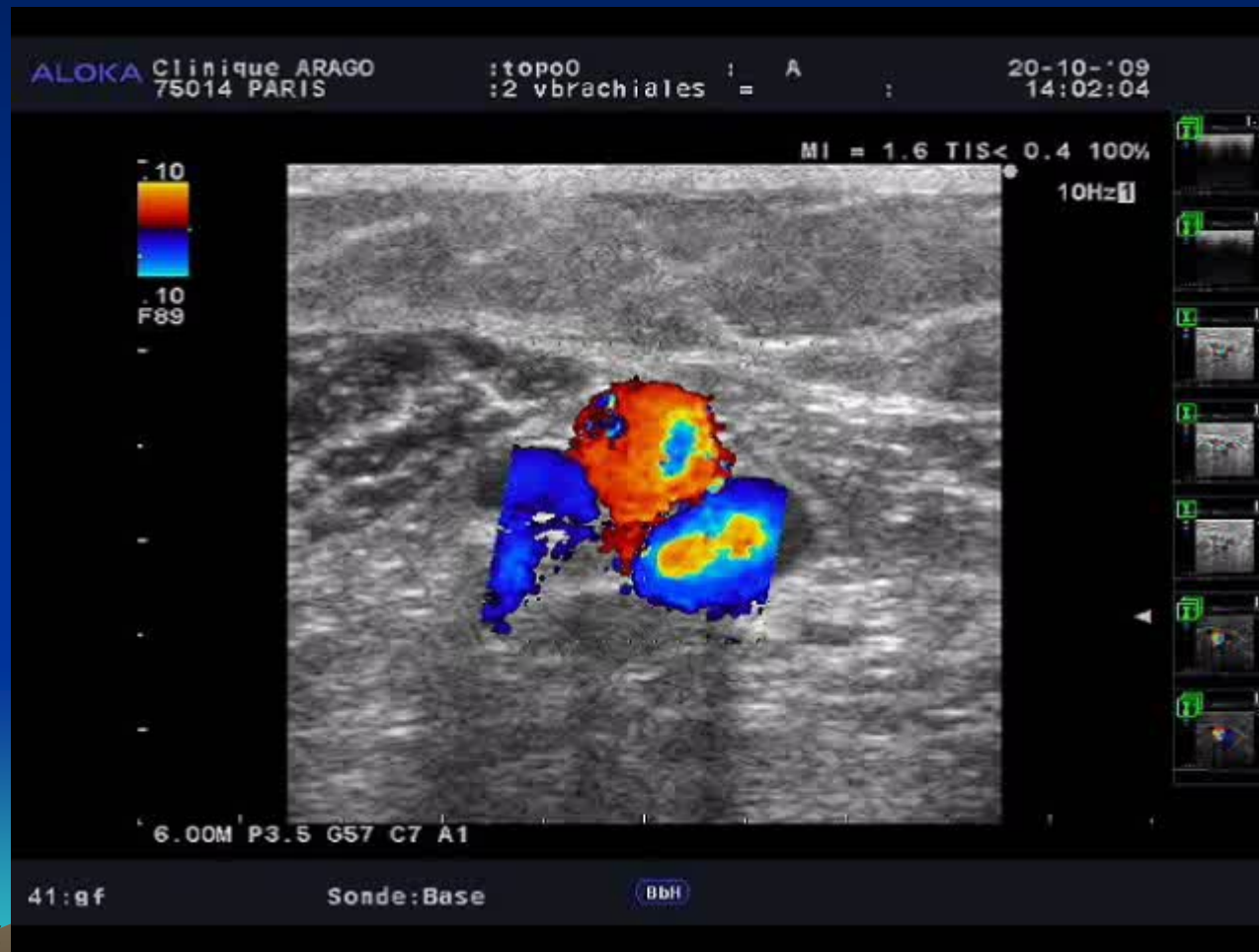COUDE




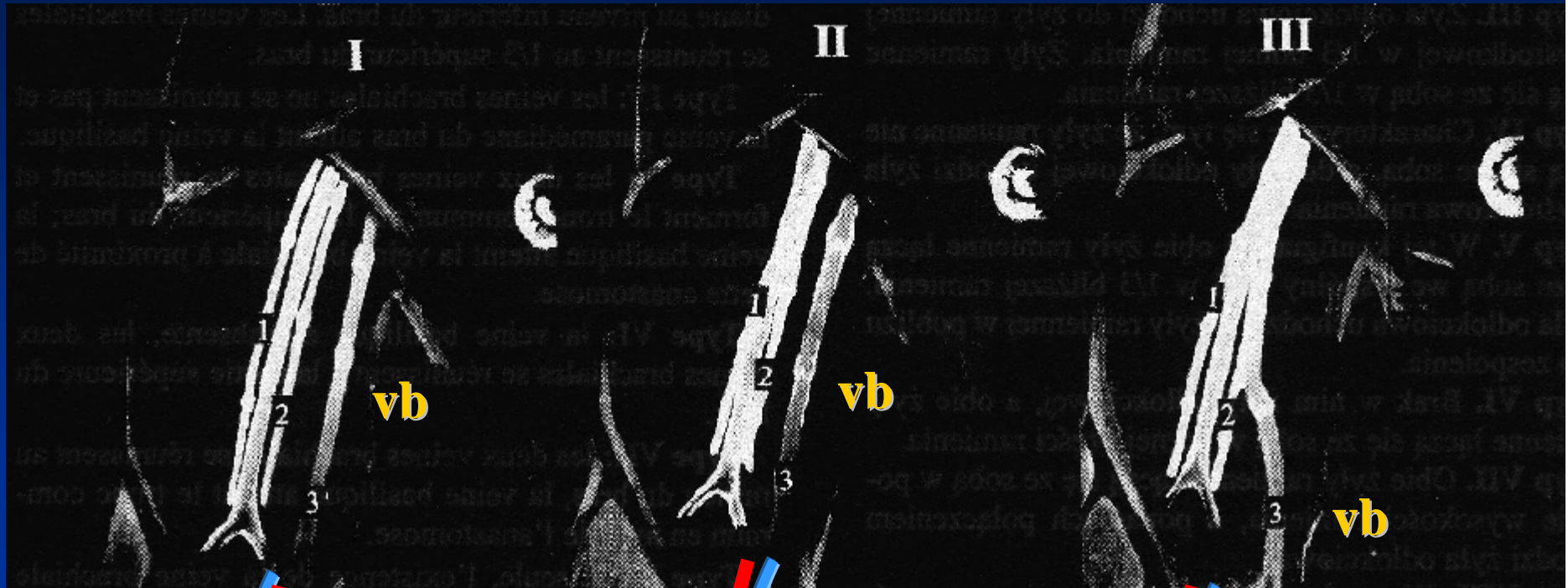
V. BASILIQUE V.BRACHIALE MEDIANE

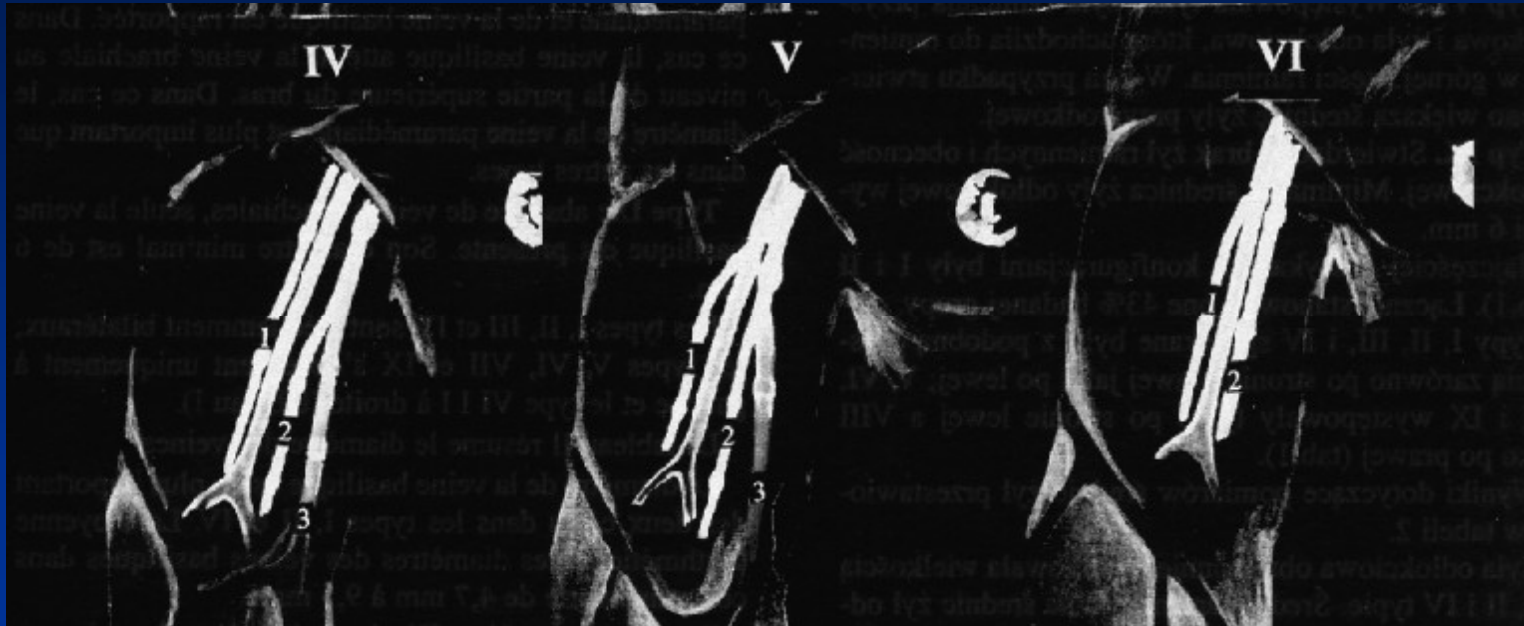





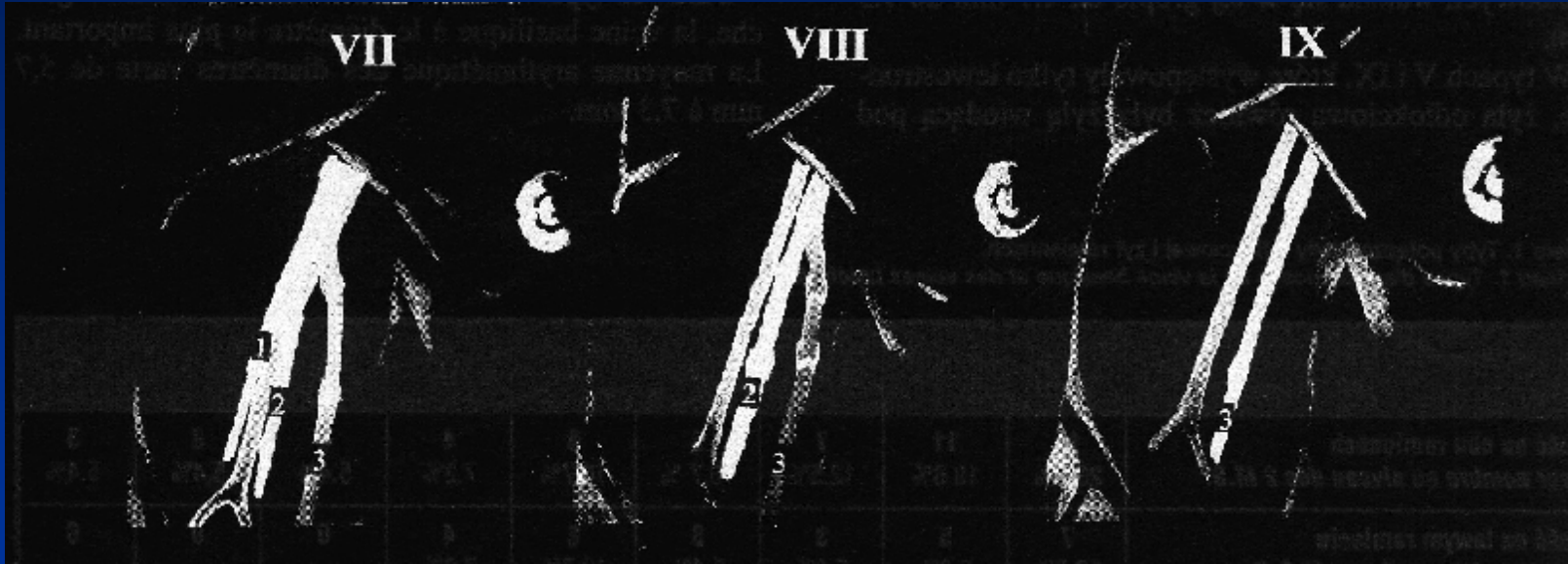
MAPPING B MODE EFLOW



Arm : three portions (proximal, medial and distal)







common brachial vein (CBV)

- seldom mentioned in medical routine
- junction of the medial brachial vein with the lateral brachial vein.
- CBV present in 73%. mean length :136 mm
- CBV : diameter 5.4 mm
- presenting 1valve for each third
- level in which the CBV was formed and its continuity along the upper limb.
- CBV presents a route closely associated with the brachial artery

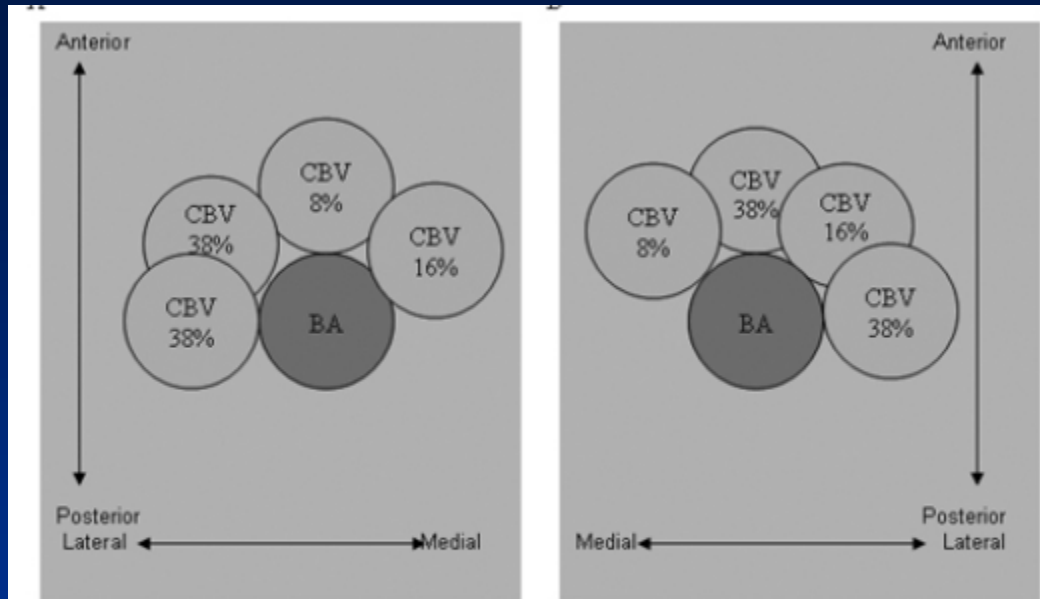


Figure 6 - Graphic representation of syntopy of the common brachial vein, in a cross-sectional view, at the intermediate point of the proximal third of the right (A) and left arm (B)

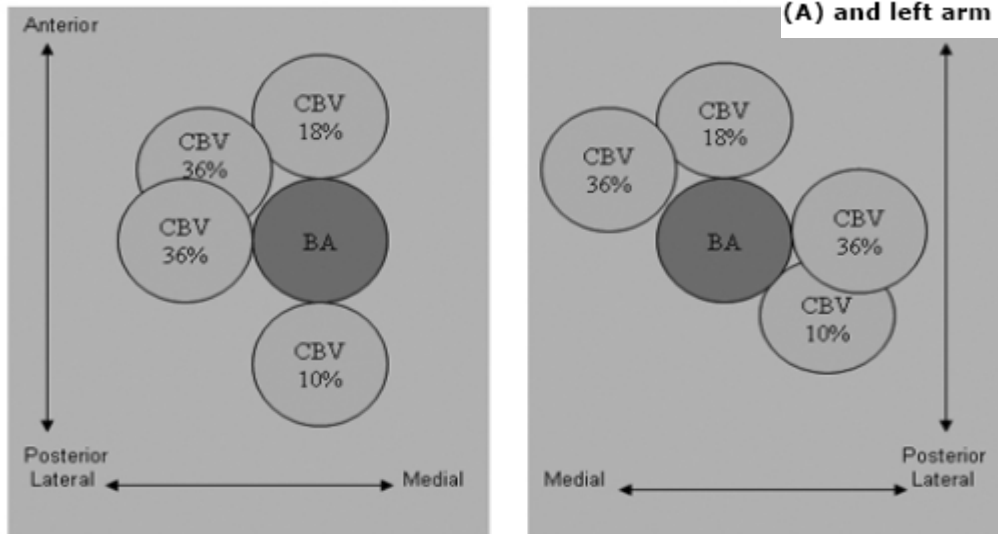
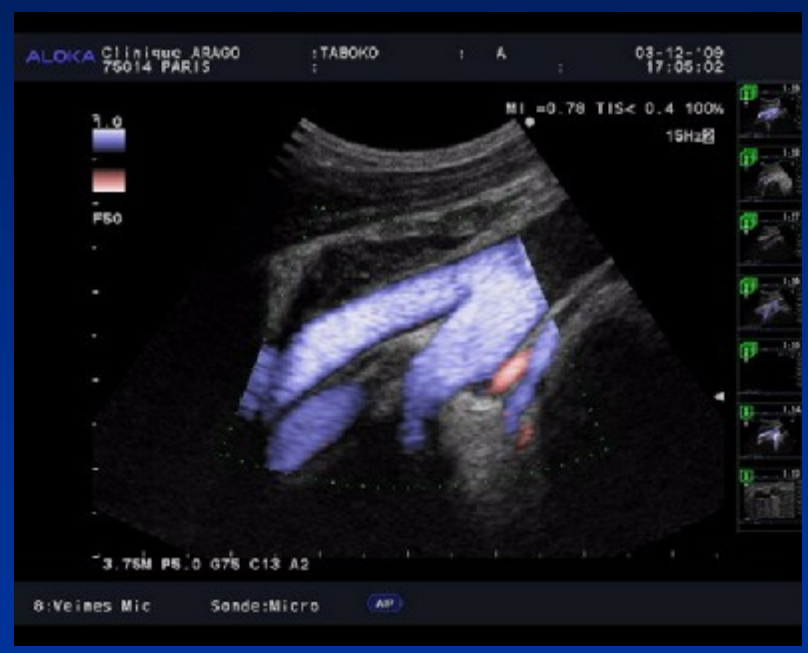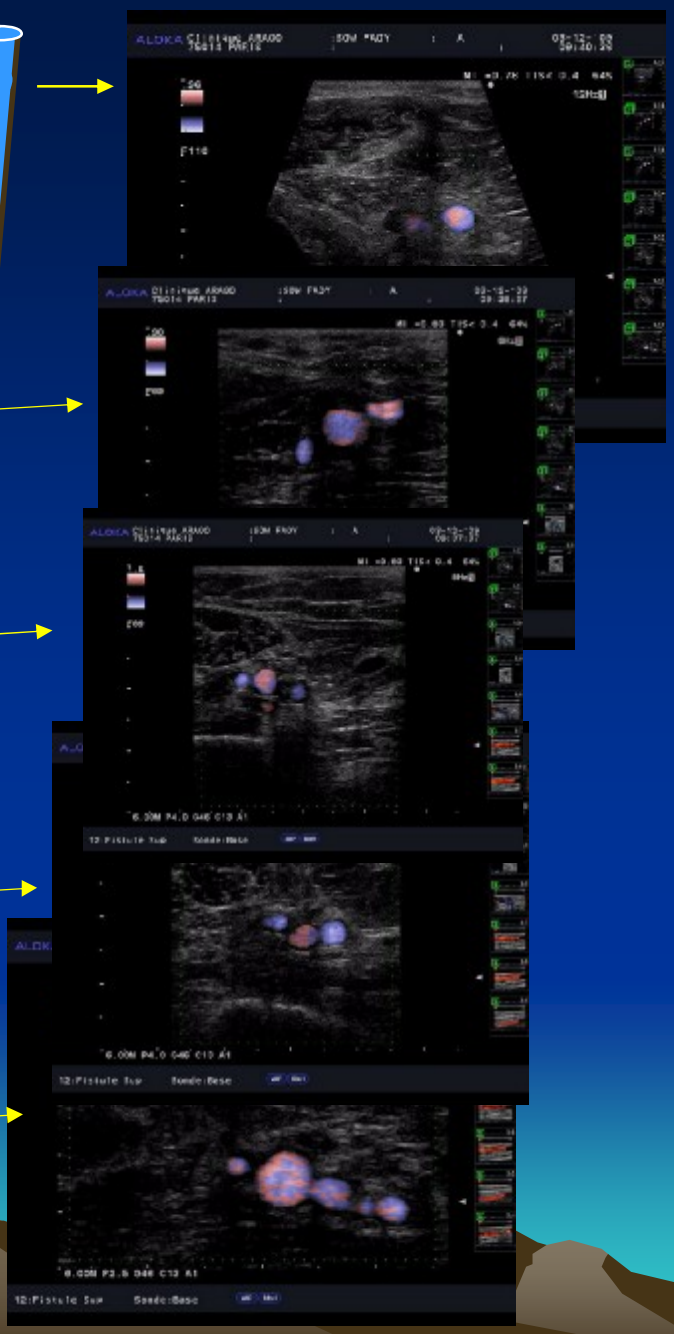

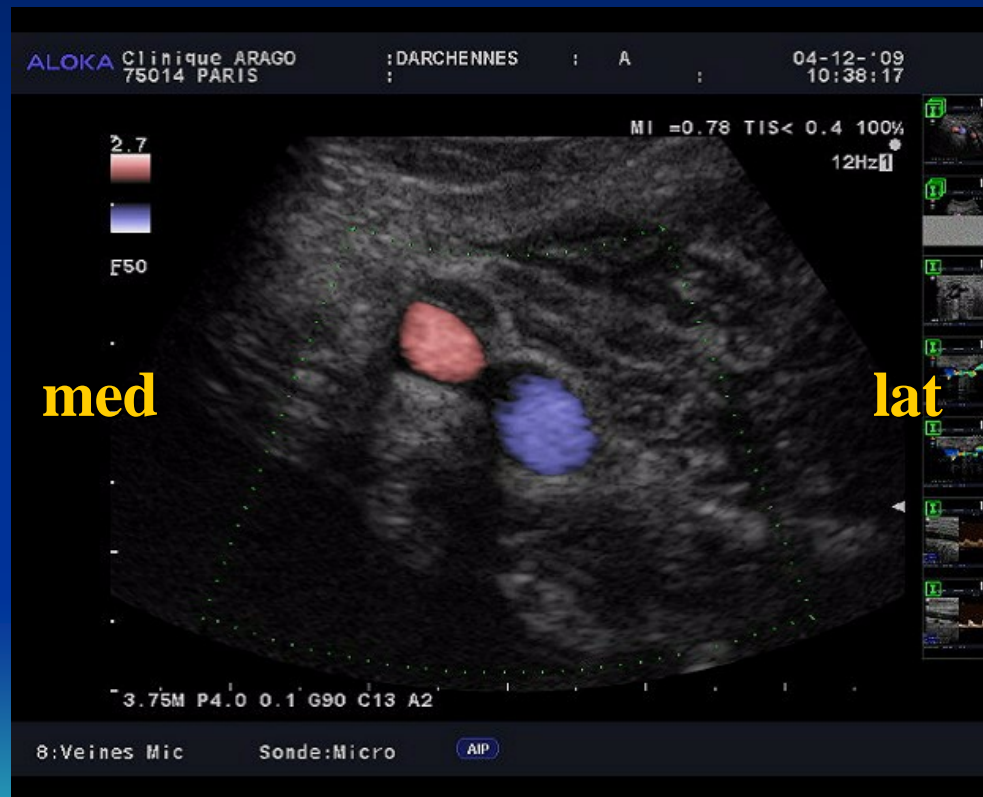


Figure 5 - Graphic representation of syntopy of the common brachial vein, in a cross-sectional view, at the intermediate point of the medial third of the right (A) and left arm (B)



CORKSCREW VEIN



Left upper limb

Dominant Lbv

**On ne trouve que ce que l' on cherche
On ne cherche que ce que l'on connaît**

II Y ENCORE DU TRAVAIL

