

**MICROSURGERY AND PREVENTIVE HAEMOSTASIS  
FOR DISTAL RADIO-CEPHALIC ARTERIO-VEINOUS FISTULA  
IN ADULT**

**Nicola Pirozzi**

# DISTAL RADIO-CEPHALIC AVF

**Best vascular access for chronic haemodialysis**

***K-DOQI***

***VAS guidelines***

- Long term patency
- Rate of complication

# DISTAL RADIO-CEPHALIC AVF

## *Early failure*

**Fistula not usable for dialysis  
(early thrombosis - lack of maturation)**

***Up to 50%***

*Allon et al, Kid.Int. 62:2002*

***Pooled estimated rate 15,3%***

*Rooijens et al, Eur J Vasc Endovasc Surg 28, 2004*

- **Comorbidity factors**  
(hypertension - diabetes - obesity - vasculopathy)
- **Vessels quality and diameter**

# DISTAL RADIO-CEPHALIC AVF

## *Early failure*

**Microsurgery and preventive haemostasis in paediatric population**

**Early failure: 5-10%**

*Bourquelot, Eur J Vasc Endovasc Surg 32, 2006*

*Bagolan et al, J Vasc Surg 27, 1998*

*Bourquelot, Microsurgery 14, 1993*

# MICROSURGERY

- Extreme precision even on small and difficult vessel
- Favour the respect of the structure anatomy

# PREVENTIVE HAEMOSTASIS

- Operative field visualization
- Reduced traumatism of the vascular wall
  - Vascular clamp unnecessary
  - No dissection of radial artery
- Loco-regional anesthesia (plexic block)

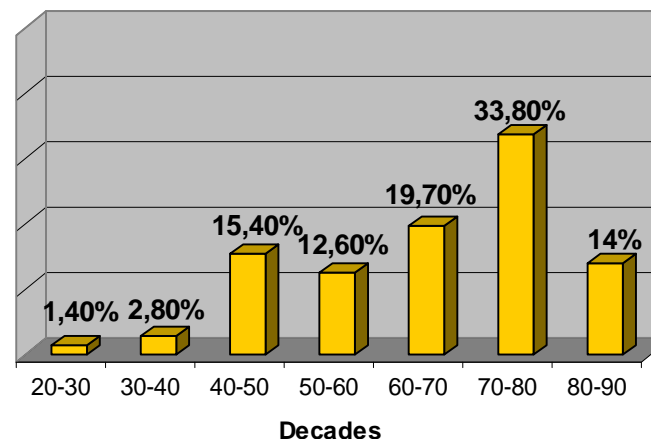
# Single centre experience

## MATERIALS AND METHOD

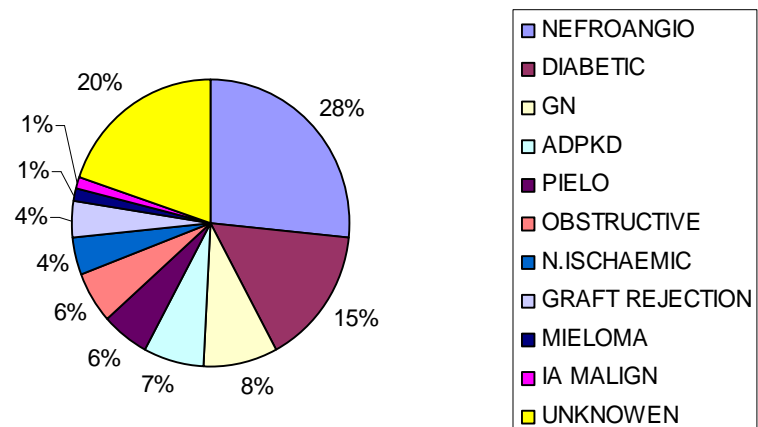
Nov 04 – Nov 06 (25 month)

<b>Incident patients</b>	<b>71</b>
<b>Age (median, DS)</b>	<b>66 +/- 14,45%</b>
<b>M/F</b>	<b>43/28</b>
<b>Age &gt; 65y</b>	<b>63%</b>
<b>HT</b>	<b>94%</b>
<b>Diabetes</b>	<b>29%</b>
<b>Obesity (BMI &gt;30)</b>	<b>15%</b>
<b>Vasculopathy</b>	<b>46%</b>
<b>Vascular calcification</b>	<b>49%</b>

Distribution for age

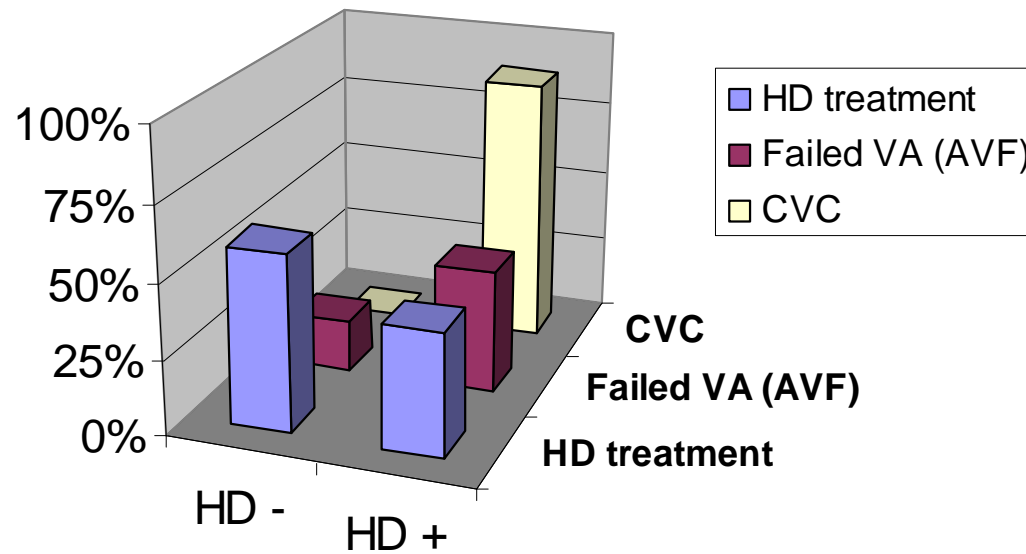


Cause of ESRD



# MATERIALS AND METHOD

## Distribution for HD treatment



	HD -	HD +
■ HD treatment	59%	41%
■ Failed VA (AVF)	17%	41%
■ CVC	0%	89%

## MATERIALS AND METHOD

Indication for distal radio-cephalic AVF: permeable vessels independently from diameter

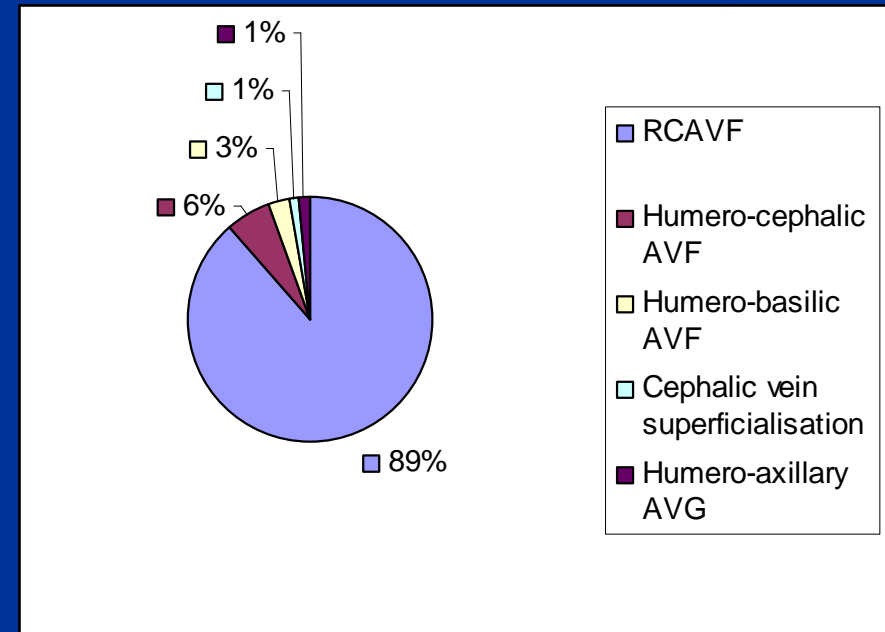
63 patients: distal RCAVF (88,7%)

4 humero-cephalic AVF

2 humero-basilic AVF

1 superficialisation of cephalic vein

1 humero-axillary PTFE



# RESULTS

## Early failure: 7,9% (5/63pts)

- thrombosis <24h after surgery in 0 pts
- thrombosis >1week after surgery in 1 pts
- lack of maturation (patent but unfunctional AVF) due to:
  - iuxta-anastomotic vein stenosis in 3 pts
  - mid vein stenosis in 1pts.

## Treatment:

Surgical revision (proximalisation at forearm of anastomosis): 4 pts

Loss of vascular access - new AVF constructed (distal ulnar-basilic): 1pts

# RESULTS

## Follow-up

35 patient would have completed a 1 year follow-up  
4 died and 2 lost

**Primary patency (1 y 29pts):70,3%**

**Primary assisted patency (1y): 93,1% (27/29)**

Intervention needed to maintain patency:  
3 surgical and 1 radiological (PTA) revision

## CONCLUSION

Micorsurgery and preventive haemostasis allowed the construction of a distal radio-cephalic AVF with a low early failure rate in a good proportion of an adult population